

CASE REPORT

Shared decision-making at end-of-life is aided by graphical trending of illness severity

David B Bittleman,¹ Alan B Solinger,² G Duncan Finlay²

¹Intercoastal Medical Group,
Sarasota, Florida, USA
²F.A.R. Institute, Sarasota,
Florida, USA

Correspondence to

Dr G Duncan Finlay,
steven.rothman@farinstitute.org

SUMMARY

The Rothman Index (RI) gives a visual picture of patient's condition and progress for the physician and family to view together. This case demonstrates how the RI graph facilitates physician–family communication. An 85-year-old man with normal pressure hydrocephalus and ventriculoperitoneal shunt presented with a subdural haematoma. He required a temporoparietal craniotomy and evacuation of left subdural haematoma, followed by care in an intensive inpatient rehabilitation unit. His course was complicated by aspiration pneumonia, dehydration, renal failure and phenytoin toxicity. During hospitalisation, the patient's RI graph was reviewed daily with his family. The RI provided an unambiguous visualisation of the trend of patient acuity, which depicted the patient's persistent decline in health, and made clear to the family the situation of the patient. This clarity was instrumental in prompting frank discussions of prognosis and consideration of comfort measures, resulting in timely transfer to hospice.

BACKGROUND

As physician communication with a patient's family is an important part of care, especially when addressing end-of-life issues, it is valuable to know that the Rothman Index (RI) can contribute significantly in this effort.^{1–4} Ideally, clear articulation of patient progress and prognosis should be a daily goal. However, variable understanding of the prognosis, by both caregivers and family members, combined with time constraints and the complex nature of multiple problems in one patient makes it a challenge. Physicians tend to avoid discussions with patients and families about poor prognoses, as accurate prognoses cannot be made and there may be fear of precipitating depression, diminishing hope and/or lowering survival expectations. Yet these concerns are not substantiated by recent reports.⁵ Furthermore, a recent pilot trial using decision support graphs proved to be helpful in communicating with patients suffering incurable cancers.⁶ The RI can be used in the same way to catalyse communication.

The RI, which is produced automatically by the hospital software from data entered into the hospital electronic health record (EHR), is available to caregivers via the EHR in the form of an easily understood line graph of patient's condition trend. It is currently being utilised at Yale – New Haven Hospitals, Shands – University of Florida Hospitals, Shanon Medical Center, Sarasota Memorial Hospital and several other hospitals. As a numerical index, it reflects patient acuity, starting at 100 and

reduced as a function of increasing risk. It is based on summing risks associated with data contained in the EHR and is continuously updated, as new data on vital signs, nursing assessments and laboratory test results are entered into the EHR. It is displayed as a simple line graph (see the accompanying figure 1) showing the current and past values of the index, easily allowing the trend of patient progress to be ascertained visually. The RI graph goes up as the patient improves, and downtrends as the patient's condition deteriorates. If the clinician wishes the specific clinical data inputs that give rise to any point on the graph, these are obtained by simply clicking on the point displayed. Thus, the RI affords the healthcare professionals consolidated, easy access to both patient overall health status and specific clinical data, as well as the trend of patient acuity. It makes even subtle changes in acuity, including progress towards health or deterioration, evident to caregivers as they occur. This case report illustrates a novel use for the RI by demonstrating how it may be used to communicate a declining patient's status to concerned family members effectively, affording candid and open discussions regarding patient treatment and comfort options.

CASE PRESENTATION

An 85-year-old frail man with normal pressure hydrocephalus and ventriculoperitoneal shunt fell at home. He presented in the emergency department of Sarasota Memorial Hospital with a 9 mm subdural haematoma, was admitted and then discharged after overnight observation. Unfortunately, the bleeding progressed and he was re-admitted to the hospital and required a temporoparietal craniotomy and evacuation of the left subdural haematoma. For 10 days, he received care in an intensive inpatient rehabilitation unit. Subsequently, he developed aspiration pneumonia, dehydration, renal failure and phenytoin toxicity. He was treated with aztreonam and moxifloxacin and was evaluated by speech therapy. He was unable to swallow safely and would have required a feeding tube. However, this was refused by the responsible family member, who agreed after consultation with the attending physician that hospice was more appropriate. The patient went into hospice care and died soon thereafter.

DIFFERENTIAL DIAGNOSIS

Normal pressure hydrocephalus, subdural haematoma, aspiration pneumonia, dehydration, renal failure and phenytoin toxicity.



CrossMark

To cite: Bittleman DB, Solinger AB, Finlay GD. *BMJ Case Rep* Published online: [please include Day Month Year] doi:10.1136/bcr-2013-201522

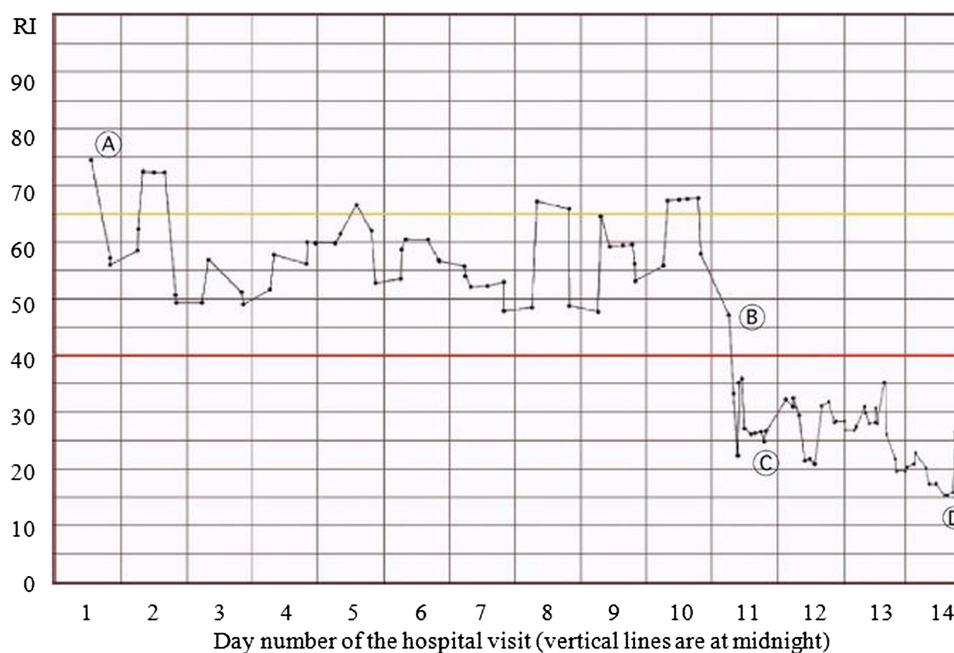


Figure 1 Rothman Index (RI) graph of patient’s course of condition, indicating initial slight decline through day 10, followed by large decrease on day 11 due to development of aspiration pneumonia, dehydration, renal failure and phenytoin toxicity. Subsequently, the RI graph reveals continued deterioration in the patient’s condition despite treatment. Point A: temporoparietal craniotomy and evacuation of left subdural haematoma were performed and the patient was admitted to the intensive inpatient rehabilitation unit. Point B: the patient develops aspiration pneumonia, renal failure, phenytoin toxicity and dehydration. Point C: the patient was treated for aspiration with aztreonam and moxifloxacin therapy. Point D: in consultation with the attending physician, and after examining the RI graph, the family makes a decision to transfer the patient to the hospice.

TREATMENT

The patient received a ventriculoperitoneal shunt, temporoparietal craniotomy and evacuation of left subdural haematoma, and subsequent aspiration and aztreonam and moxifloxacin therapy.

OUTCOME AND FOLLOW-UP

Daily care conferences were held during the hospital stay with the patient’s son, daughter, daughter-in-law and a long-time companion. The RI was reviewed at each visit (see figure 1). The RI, which displayed graphically the patient’s steady and continuing decline in health, made clear to the family the situation of the patient. This clarity was instrumental in prompting frank discussions of prognosis and possible palliative measures. The presence of ongoing aspiration and the patient’s failure to respond to appropriate antibiotic and other supportive treatments made further medical care imprudent. With the ability of the family to visualise the deterioration of the patient, broaching the conversation about his condition was straightforward and the decision was made with relative ease to enrol him in hospice care, where he had a peaceful death. Subsequently, the patient’s long-time companion wrote saying that the RI “...really helped (me) to understand ... (the patient)’s true condition setting aside the emotional issues.”

DISCUSSION

Recent studies examining physician communication with family members of intensive care unit patients showed that families want the physician to be empathetic and provide honest prognostic information. Examination of audiotaped physician–family conferences about life-support decisions in the intensive care unit setting showed that the physician’s ability to communicate prognosis was poor. Families doubt the ability of physicians to

predict death, but they value the chance to have an open discussion about whether or not it is imminent.^{6 7}

The RI shows graphically both the current health status of the patient and the trend of the patient’s condition during his stay in the hospital, as well as making available to the physician vital signs, laboratory test results and nursing assessments at any point with a simple mouse click (or touch on an Apple iPad screen). As such, it is an invaluable tool to provide caregivers and family alike an objective answer to the common and difficult questions: “Doc, how is he/she doing? Is he/she getting better?” While various consultants will comment on the patient’s organ system, they often leave this general and difficult question to the primary doctor. For the primary internist, sitting with the patient’s family and reviewing the day’s events with the

Learning points

- ▶ Families of sick patients want caregivers to talk to them, frankly discuss the facts pertaining to the acuity status of the patient and formulate prognoses.
- ▶ The Rothman Index (RI) presents a visual representation of patient’s acuity trend and status that is easily understood by non-medically trained persons, and facilitates discussion of patient progress, whether towards improvement or decline.
- ▶ The RI can help the physician initiate discussions about end-of-life care and hospice in patients who are dying because it simply presents the evidence, without judgement or emotion.
- ▶ Physicians can utilise the RI to communicate better about many issues involving patient’s condition and progress and help make plans for patient disposition.

RI graph greatly facilitated communication in a variety of clinical circumstances. Furthermore, the RI graph has helped initiate discussions specifically about end-of-life care and hospice in patients who are dying because it presents the evidence simply and clearly, without judgement or emotion.

Sick patients' families need empathetic help in understanding their loved-ones' illness. In this and many other similar cases, the RI has served as an important visual aid in facilitating these important conversations and ultimately providing a higher level of satisfaction with hospital care.

Contributors DBB was attending physician for the case and wrote the initial report. ABS and GDF discussed the case in detail with DBB, and completed the case write-up, including supervising the production of the figure. All authors have edited and approved the final manuscript.

Competing interests DBB and ABS declare none. GDF declares none as President of the F.A.R. Institute in Sarasota, Florida, USA. GDF is part-time Chief Medical Officer and owns stock of PeraHealth, incorporated in Charlotte, North Carolina, USA. This commercial company had no connection with this report and no knowledge of the foundation's study.

Patient consent Obtained.

Provenance and peer review Not commissioned; externally peer reviewed.

REFERENCES

- Bradley EH, Yakusheva O, Horwitz LI, *et al.* Identifying patients at increased risk for unplanned readmission. *Med Care* 2013;51:761–6.
- Rothman MJ, Rothman SI, Beals J IV. Development and validation of a continuous measure of patient condition using the electronic medical record. *J Biomed Inform* 2013;46:837–48.
- Rothman SI, Rothman MJ, Solinger AB. Placing clinical variables on a common linear scale of empirically based risk as a step towards construction of a general patient acuity score from the electronic health record: a modelling study. *BMJ Open* 2013;3:e002367.
- Rothman MJ, Solinger AB, Rothman SI, *et al.* Clinical implications and validity of nursing assessments: a longitudinal measure of patient condition from analysis of the Electronic Medical Record. *BMJ Open* 2012;2:e000646.
- Mack JW, Smith TJ. Reasons why physicians do not have discussions about poor prognosis, why it matters, and what can be improved. *J Clin Oncol* 2012;30:2715–17.
- Smith TJ, Dow LA, Virago EA, *et al.* A pilot trial of decision aids to give truthful prognostic and treatment information to chemotherapy patients with advanced cancer. *J Support Oncol* 2011;9:79–86.
- White DB, Engelberg RA, Wenrich MD, *et al.* Prognostication during physician-family discussions about limiting life support in intensive care units. *Crit Care Med* 2007;35:442–8.

Copyright 2014 BMJ Publishing Group. All rights reserved. For permission to reuse any of this content visit <http://group.bmj.com/group/rights-licensing/permissions>.
BMJ Case Report Fellows may re-use this article for personal use and teaching without any further permission.

Become a Fellow of BMJ Case Reports today and you can:

- ▶ Submit as many cases as you like
- ▶ Enjoy fast sympathetic peer review and rapid publication of accepted articles
- ▶ Access all the published articles
- ▶ Re-use any of the published material for personal use and teaching without further permission

For information on Institutional Fellowships contact consortiasales@bmjgroup.com

Visit casereports.bmj.com for more articles like this and to become a Fellow